

## Case Report

# Immature teratoma of the ovary: A Pandora's box-an oncologist's perspective

Antara Sanyal<sup>1</sup>, Soumya Surath Panda<sup>1</sup>, Manas Baisakh<sup>2</sup>, Adya Kinkar Panda<sup>3</sup>, Swati Sucharita Mohanty<sup>1</sup>, Sujata Naik<sup>4</sup>

<sup>1</sup>Department of Medical Oncology, Institute of Medical Sciences and Sum Hospital, Siksha 'O' Anusandhan Deemed to be University, <sup>2</sup>Department of Pathology, Prolife Diagnostics, Departments of <sup>3</sup>Radiology and <sup>4</sup>Pathology, Institute of Medical Sciences and Sum Hospital, Siksha 'O' Anusandhan Deemed to be University, Bhubaneswar, Odisha, India.



### \*Corresponding author:

Soumya Surath Panda,  
Department of Medical  
Oncology, Institute of Medical  
Sciences and Sum Hospital,  
Siksha "O" Anusandhan  
Deemed to be University,  
Bhubaneswar, Odisha, India.

soumyasurathpanda@soa.ac.in

Received: 07 January 2025  
Accepted: 11 February 2025  
Epub Ahead of Print: 15 April 2025  
Published:

DOI  
10.25259/IJMIO\_1\_2025

Quick Response Code:



## ABSTRACT

Malignancy rarely arises in mature cystic teratoma; however, it tends to affect postmenopausal females – most commonly squamous cell carcinoma. Neural tissue may be found in some cases, although very rarely seen in immature teratoma. We present a case report of a 22-year-old nulliparous female with left ovarian immature teratoma – Stage-IA, Grade-3 with oligodendroglial differentiation. The case was discussed in the multidisciplinary tumor board - the patient received four cycles of systemic therapy and is now disease-free at 9 months follow-up.

**Keywords:** Adolescent and young adults, Germ cell tumors, Immature teratoma, Oligodendrogloma, Ovarian neoplasms

## INTRODUCTION

Affecting the postmenopausal population, a mature cystic teratoma typically harbors squamous cell carcinoma as the most common component.<sup>[1]</sup> However, other elements of differentiation have been previously reported.<sup>[2]</sup> Evidence-based management is the motto of oncology, even for the rarest malignancies. Therefore, it is prudent to discuss the dilemma of immature teratoma that affects the adolescent and young adult age group – a nation's future and, in our case, our patient.

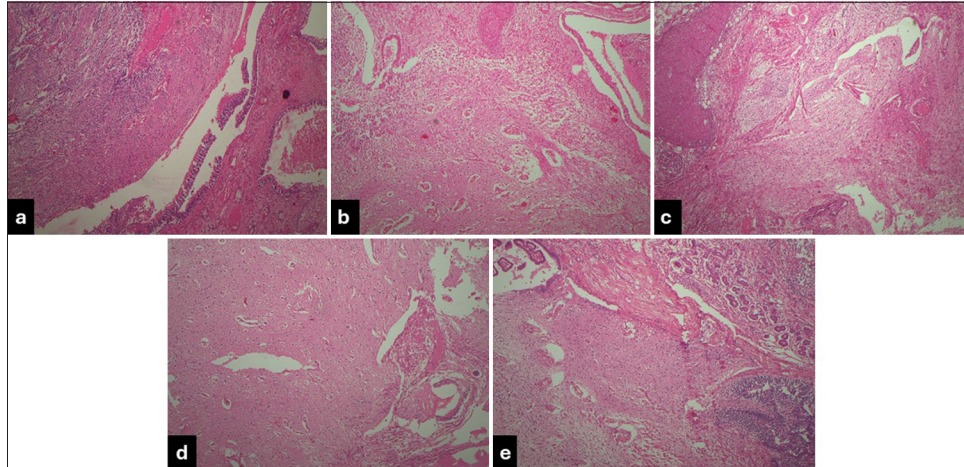
In this case report, we focused on bringing a more comprehensive and practical approach to managing a case of immature teratoma with oligodendroglial differentiation in a young lady diagnosed in the 2<sup>nd</sup> decade of her life. The Institutional Review Board approved this study, and the patient's consent was obtained.

## CASE REPORT

A 22-year-old unmarried, nulliparous female presented to our center in post-operative status with the diagnosis of an immature teratoma. The patient had initially presented with abdominal distension and pain in the lower abdomen ×3 months. Baseline tumor markers were normal. Contrast-enhanced computed tomography of the abdomen had depicted a large cystic mass in the abdominopelvic region ~17 cm, arising from the left ovary. She had undergone exploratory laparotomy and left salpingo-oophorectomy in May 2023. The post-

This is an open-access article distributed under the terms of the Creative Commons Attribution-Non Commercial-Share Alike 4.0 License, which allows others to remix, transform, and build upon the work non-commercially, as long as the author is credited and the new creations are licensed under the identical terms.

©2025 Published by Scientific Scholar on behalf of International Journal of Molecular and Immuno Oncology



**Figure 1:** Left salpingo-oophorectomy specimen: (a) Focal areas of moderately cellular neoplasm composed of round to oval tumor cells with mild pleomorphic vesicular nuclei; (b) scanty to moderate cytoplasm and perinuclear halo arranged in sheets and singles against a glio-fibrillary background; and (c) intervening stroma with frequent thin-walled branching blood vessels; (d and e). No significant mitosis, IMCT Grade-3. (200X; Hematoxylin and eosin stain).

operative histopathology report (HPR) suggested a Grade-3 left ovarian immature teratoma of size ~15 cm, with oligodendroglial differentiation; ovarian surface and fallopian tube were free of deposits – pT1a (IA), [Figure 1 a-e]. After a thorough discussion in the multidisciplinary tumor board (MDT) – National Comprehensive Cancer Network guidelines were discussed after a brief review of the literature; given Grade-3 disease, the board decided to proceed with three cycles of BEP (Inj. Bleomycin 30 IU on days – 1,8,15, Inj. Etoposide @ 100 mg/ m<sup>2</sup>/day × 5 days, Inj. Cisplatin @20 mg/m<sup>2</sup> day × 5 days) every 21 days, followed by one cycle of EP as per protocol. Post-operative imaging suggested no residual/recurrent disease with normal tumor markers. Before treatment initiation, the option of fertility preservation was discussed; however, the patient and her respondents were unwilling and signed a written consent. The patient completed three cycles of BEP. Post-3<sup>rd</sup> cycle, she was admitted for febrile neutropenia with Grade-2 diarrhea and was managed symptomatically with i/v antibiotics, anti-diarrheal measures, and supportive care. She completed cycle 4 with EP (25% dose reduction) on September 27, 2023. Tumor markers were normal post-chemotherapy completion. The case was re-discussed in MDT, and the patient was planned to be kept on 3-monthly follow-up for the first 2 years – monitoring with ultrasonography whole abdomen and pelvis and serum tumor markers and then every 4<sup>th</sup>–6<sup>th</sup> monthly till the 5<sup>th</sup> year.

The patient has a disease-free survival of 9 months at the time of writing this paper. The last follow-up was in May 2024, and the previous telephonic update was in June 2024.

## DISCUSSION

Squamous cell carcinoma is the most common malignancy arising in a mature cystic teratoma; it tends to affect the postmenopausal population.<sup>[1]</sup> Other elements of differentiation, including but not limited to gastrointestinal adenocarcinoma, sarcoma, and melanoma, have also been reported as part of various case reports.<sup>[2]</sup>

The presentation of our patient at the age of 22 years with abdominal pain corresponds to the previously reported young adult age group and chief complaint;<sup>[1-5]</sup> however, its diagnosis in the adolescent age group has also been documented.<sup>[6]</sup>

As part of primary treatment, our patient underwent exploratory laparotomy with the left salpingo-oophorectomy. On HPR, it was found to be a cystic ovary ~15 cm tumor size in largest dimension, Grade-3, with the typical histopathological finding of round to oval tumor cells having mild pleomorphic vesicular nuclei, scanty to moderate cytoplasm and perinuclear halo (fried egg appearance), arranged in sheets and singles against a glial fibrillary background, and frequent thin-walled branching blood vessels. All the microscopic findings correspond to previously published reports.<sup>[1-6]</sup> The patient tolerated three cycles of BEP and one cycle of EP with a manageable toxicity profile and was disease-free for 9 months; however, previously reported cases received systemic therapy at the time of relapse and succumbed to the disease eventually.<sup>[4]</sup> A table depicting the relevant findings from the present case report with other reported cases and a case series has been summarized below for the readers [Table 1].

**Table 1:** Review of literature: Oligodendroglioma arising in mature and immature teratomas.

Author (Year of publication and country of origin)	Reference No. (except our study)	Type of study and relevant findings (DFS at the time of last follow-up)
Sanyal <i>et al.</i> (Our Study) (India)	-	Case Report; 22-year-old nulliparous female Underwent left salpingo-oophorectomy→HPR s/o Stage-IA Grade-3 immature teratoma with oligodendroglial component Received: BEP×3 cycles→EP×1 cycle DFS→9 months
Zannoni <i>et al.</i> (2002) (Italy)	[1]	Case Report; 29-year-old nulliparous female Underwent Laparotomy with the right ovariectomy HPR s/o mature cystic teratoma with oligodendroglial component IHC: GFAP, NFP+/Leu-7 focally+/NSE, Synaptophysin – DFS→48 months
Caltabiano and Lanzafame (2008) (Italy)	[2]	Case Report; 18-year-old female HPR s/o immature teratoma with oligodendroglial component IHC: S100+/GFAP, NSE, Synaptophysin – DFS→24 months
Opris <i>et al.</i> (2009) (France)	[3]	Case Report; 29-year-old multiparous female Underwent laparotomy with left ovariectomy HPR s/o mature cystic teratoma with oligodendroglial component IHC: GFAP, NFP+/Synaptophysin–/Ki-67: 3% RT-PCR: LOH on Chromosomes 10q and 19q13 DFS→10 months
Bay <i>et al.</i> (2010) (Turkey)	[6]	Case Report; 13-year-old female Underwent oophorectomy HPR s/o mature cystic teratoma with oligodendroglial component IHC: S100+/GFAP, Synaptophysin–/Ki-67: 2% DFS→9 months
Ud Din <i>et al.</i> (2012) (Pakistan)	[4]	Retrospective case series of 6 cases; Age group: 12–28 years (Mean 21 years) All underwent surgery HPR s/o 2 mature and 4 immature cystic teratoma with oligodendroglial component; all WHO Grade-2 IHC: Synaptophysin–/Ki-67: 2–4% DFS range→1–42 months (2 Immature teratoma cases: OS→1 and 36 months)
Ünal <i>et al.</i> (2014) (Turkey)	[5]	Case Report; 18-year-old female Underwent laparotomy+right oophorectomy HPR s/o mature cystic teratoma with oligodendroglial component IHC: GFAP, EGFR, p53+/Ki-67: 2–5% DFS→13 months

HPR: Histopathology report, DFS: Disease-free survival, GFAP: Glial fibrillary acidic protein, IHC: Immunohistochemistry, EGFR: Epidermal growth factor receptor, NFP: Neurofilament protein, NSE: Neuron-specific enolase, WHO: World Health Organization, BEP: Bleomycin, etoposide and platinum, BEP: Bleomycin, etoposide and platinum, RT-PCR: Reverse transcription-Polymerase chain reaction, LOH: Loss of heterozygosity.

Despite our report being limited to a single patient's data, we cannot undermine that it helped us to understand the dictum “the eyes don't see what the mind doesn't know” – this rarest form of presentation of immature teratoma with oligodendroglial differentiation. An early surgical intervention followed by systemic therapy with BEP, in this case of Stage-IA Grade-3, is prudent to prevent relapse and or recurrence for better survival outcomes. This entity is sensitive because this is the age group of women that constitutes the fertile population and thereby affects all aspects of health. Ultimately, the goal is to help achieve an

overall normal life expectancy, a good quality of life, and fertility preservation through oocyte banking and early surgical intervention, as most cases are localized to a single ovary.

#### New knowledge and learning points

- Oligodendroglial differentiation in immature teratoma is a rare finding, indicating poor overall survival.
- The oligodendroglial component will not change our treatment approach.

As per established guidelines, these patients will inadvertently benefit from adjuvant BEP chemotherapy.

## CONCLUSION

Our case highlights the importance of rigorous histological and immunohistochemical examination in patients with immature teratoma. As rare as it may be, such specimens can harbor neural tissue elements, including the rarest of them all, an oligodendroglioma. These patients should be promptly treated based on the stage and grade of the mature/immature teratomas as per institutional guidelines since neural elements, especially oligodendroglial components, are a harbinger of worse prognosis and should be nipped at its bud to improve the survival outcomes.

**Ethical approval:** The Institutional Review Board has waived the ethical approval for this study.

**Declaration of patient consent:** The authors certify that they have obtained all appropriate patient consent.

**Financial support and sponsorship:** Nil

**Conflicts of interest:** There are no conflicts of interest.

**Use of artificial intelligence (AI)-assisted technology for manuscript preparation:** The authors confirm that there was no use of artificial intelligence (AI)-assisted technology for assisting in the writing or editing of the manuscript and no images were manipulated using AI.

## REFERENCES

1. Zannoni GF, Fadda G, Scambia G, Capelli A, Carbone A. Oligodendroglioma arising within a mature cystic ovarian teratoma: Case report and review of the literature. *Acta Obstet Gynecol Scand* 2002;81:896-7.
2. Caltabiano R, Lanzafame S. Oligodendroglioma arising in an immature ovarian teratoma: Case report. *Pathologica* 2008;100:420-3.
3. Opris I, Ducrotoy V, Bossut J, Lamy A, Sabourin JC. Oligodendroglioma arising in an ovarian mature cystic teratoma. *Int J Gynecol Pathol* 2009;28:367-71.
4. Ud Din N, Memon A, Aftab K, Ahmad Z, Ahmed R, Hassan S. Oligodendroglioma arising in the glial component of ovarian teratomas: A series of six cases and review of literature. *J Clin Pathol* 2012;65:631-4.
5. Ünal B, Güleç F, Şedele M. Oligodendroglioma arising in mature cystic teratoma. *Case Rep Oncol Med* 2014;2014:745462.
6. Bay SB, Corapcioglu F, Kavurt S, Müezzinoğlu B, Anik Y, Tugay M. Oligodendroglioma arising in a mature cystic ovarian teratoma in a child. *Pediatr Hematol Oncol* 2010;27:636-40.

**How to cite this article:** Sanyal A, Panda SS, Baisakh M, Panda AK, Mohanty SS, Naik S. Immature teratoma of the ovary: A Pandora's Box-an oncologist's perspective. *Int J Mol Immuno Oncol*. doi: 10.25259/IJMIO\_1\_2025