

Primary adenoid cystic carcinoma of the liver: A case report

Padmaj S. Kulkarni¹, Girish Phadke², Mahesh M. Mandolkar³, Sujit Nilegaonkar⁴, Sonali Deshmukh⁵

Departments of ¹Medical Oncology, ²Surgical Oncology, ³Pathology, ⁴Nuclear Medicine, ⁵Radiology, Deenanath Mangeshkar Hospital, Pune, Maharashtra, India

Correspondence to: Dr. Padmaj S. Kulkarni, Deenanath Mangeshkar Hospital, Pune, Maharashtra, India. E-mail: padmaj.kulkarni@gmail.com

ABSTRACT

Adenoid cystic carcinoma (ACC) is primarily found in the salivary glands and rarely at other organs but never reported as liver primary. This is a very rare case of primary ACC of the liver which was not resectable and managed with chemotherapy and targeted therapy. The patient progressed on imatinib (c-kit positive) while responded to chemotherapy and gefitinib (epidermal growth factor receptor mutation absent).

Key words: Adenoid cystic carcinoma, Liver primary, Chemotherapy, Targeted therapy

Introduction

Adenoid cystic carcinoma (ACC) is a slow growing but aggressive neoplasm of the salivary glands. Other uncommon primary sites of ACC include breast, trachea, lacrimal glands, skin, and vulva.^[1] Aggressive surgical resection with or without post-operative radiotherapy is the mainstay of treatment of non-metastatic ACC. The incidence of distant metastases of ACC ranges from 35% to 50%,^[1] with lungs being the most common site. However, ACC is also known to metastasize to other organs such as liver, kidney, bones, and brain.^[2,3]

Metastatic ACC is treated with palliative chemotherapy. ACC is a chemo-resistant tumor, and though various chemotherapeutic agents have been tried, the reported response rates of ACC to chemotherapy are varied, inconsistent, and generally poor.^[4]

To the best of our knowledge, primary ACC of the liver has never been reported in literature, and hence, treatment for such cases is not yet clear. Here, we report a case of ACC with the liver as primary site and treatment modalities utilized for the same.

Case Report

A 31-year-old male presented to Deenanath Mangeshkar Hospital with complaint of pain in upper abdomen since 2 months and epigastric swelling since 7 days. There was no significant past history. Clinical examination showed an abdominal lump in right hypochondriac and epigastric regions. An ultrasound examination and computerized tomography (CT) scan of the abdomen and pelvis showed a mass in left and caudate lobes of the liver. Positron emission tomography CT (PETCT) scan showed a 12.4 cm × 11.2 cm × 12 cm lesion in left and caudate lobes of liver abutting the body of pancreas and antropyloric region

of the stomach with loss of intervening fat planes (Figure 1). The lesion was associated with fluorodeoxyglucose (FDG) avid periportal lymph nodes and multiple omental deposits. There was no evidence of any lesion outside abdomen clinically as well on PETCT. In particular, examination of the oral cavity and head neck region was normal, and there was no history of any dental or gum problems or surgery. Tumor markers alpha-fetoprotein and cancer antigen 19-9 were within normal range. Biopsy of the lesion was reported as ACC of the liver (Figure 2) and tumor was found to be c-kit positive. A diagnosis of “primary ACC of the liver” was made as there was no evidence of any other primary site.

Tumor was deemed unresectable due to extensive liver involvement, peritoneal metastases, and loss of fat planes with pancreas and stomach. As the patient was relatively asymptomatic, he was started on treatment with imatinib in view of c-kit positivity. However, PETCT scan done after 1 month showed progression of disease with appearance of new lesions and increase in size (13.6 cm × 11.3 cm × 12.3 cm) and standardized up take value (SUV 6.7 vs. 4.3) of old lesions with increased pain. Hence, imatinib was stopped and he was treated with cyclophosphamide doxorubicin cisplatin (CAP) combination chemotherapy for six cycles. A CT scan done at this time was suggestive of stable disease. In view of good symptomatic relief with CAP, he was given 3 more cycles of same chemotherapy. The liver lesion reduced in size to 12.6 cm × 10.2 cm × 11.4 cm as also the regional nodes. There was also reduction in size, number, and FDG activity of peritoneal deposits. However, the lesion was still found to be unresectable. There was significant improvement in his symptoms, but the pain still persisted, he felt tired and had reduced appetite. The patient was reluctant for injectable chemotherapy and wanted oral therapy for better symptom control.

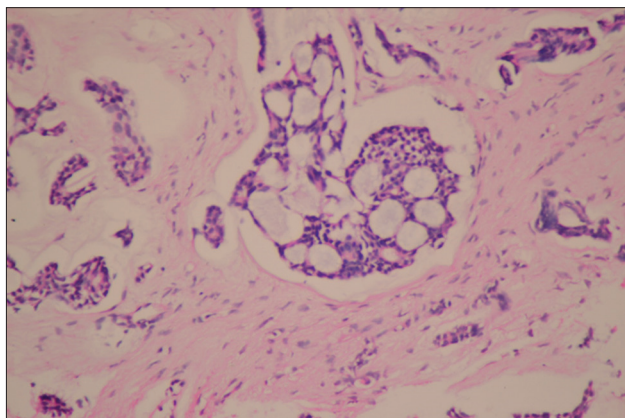


Figure 2: Adenoicyc carcinoma histology (H & E, 40X)

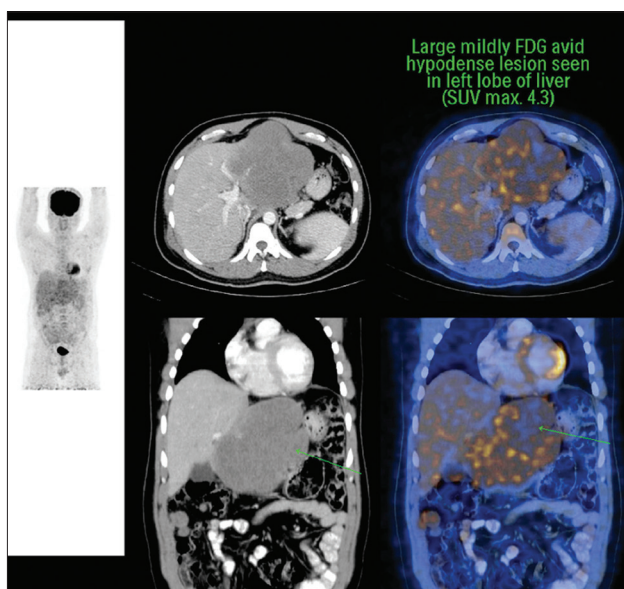


Figure 1: PECTCT scan (Baseline)

A Phase II study of gefitinib in patients with primary head and neck adenoid cystic as well as mucoepidermoid carcinoma showed disease stabilization in 10 of 36 evaluable patients. The response was maintained for at least 16 weeks in 5 patients.^[5] Hence, the patient was started on treatment with gefitinib at a dose of 250 mg per day. However, his tumor was negative epidermal growth factor receptor mutations. He tolerated the treatment well and became asymptomatic in a month with improved performance status. A CT scan done after 6 months

was suggestive of stable disease and gefitinib was continued. A disease evaluation with CT scan after 1 year of treatment with gefitinib showed stable primary with appearance of new peritoneal lesions. However, the patient was asymptomatic and chose to continue with gefitinib. After 18 months of treatment, he started getting severe aphthous ulcers in the mouth which regressed off treatment. He then continued with intermittent courses of gefitinib titrated with development and regression of mouth ulcers. A CT scan after 24 months of therapy showed progression in primary as well as metastases. Patient developed pain in abdomen, loss of appetite, and weight loss over next 2 months and has now been offered palliative care.

Conclusion

This case shows very rare presentation of primary ACC of the liver which progressed on imatinib though the tumor was c-kit positive. However, he responded to gefitinib with sustained response even though the tumor was EGR mutation negative. The intracellular transductive pathways are very complicated, and more research is needed to understand the mechanism of action of various drugs acting on these pathways. He responded to standard chemotherapy with CAP with partial response. ACC may respond to traditional chemotherapy in some patients. Newer targeted therapies offer new hope for patients suffering from this rare disease.

References

1. Bradley PJ. Distant metastases from salivary glands cancer. *ORL J Otorhinolaryngol Relat Spec* 2001;63:233-42.
2. Moskaluk CA. Adenoid cystic carcinoma: Clinical and molecular features. *Head Neck Pathol* 2013;7:17-22.
3. Bradley PJ. Adenoid cystic carcinoma of the head and neck: A review. *Curr Opin Otolaryngol Head Neck Surg* 2004;12:127-32.
4. Dodd RL, Slevin NJ. Salivary gland adenoid cystic carcinoma: A review of chemotherapy and molecular therapies. *Oral Oncol* 2006;42:759-69.
5. Jakob JA, Kies MS, Glisson BS, Kupferman ME, Liu DD, Lee JJ, *et al.* Phase II study of gefitinib in patients with advanced salivary gland cancers. *Head Neck* 2015;37:644-9.

How to cite this article: Kulkarni PS, Phadke G, Mandolkar MM, Nilegaonkar S, Deshmukh S. Primary adenoid cystic carcinoma of the liver: A case report. *Int J Mol Immuno Oncol* 2017;2:20-21.

Source of Support: Nil. **Conflict of Interest:** None declared.